



Lateral Incisor Bracket Positioning for Phase I Treatment

In 1941, Broadbent described the “ugly duckling stage” of development, which occurs between ages 7 and 9 when the maxillary permanent canines begin to erupt.¹ Pressure from the canines against the lateral incisor roots initially causes them to displace mesially against the roots of the central incisors, and this force causes the central incisor roots to displace mesially as well. The resultant distal divergence of the incisor crowns produces a midline diastema.

Parents concerned about the appearance of the child’s front teeth may seek Phase I treatment with fixed appliances, but improper bracket positioning during this critical stage can interfere with canine eruption or result in iatrogenic root resorption of the lateral incisors (A). This month’s Pearl reviews bracket positioning of the maxillary lateral incisors during Phase I treatment. The recommendations are based on the MBT* bracket prescription and should be modified appropriately for Roth or Damon** prescriptions.

Technique

The slots of the lateral incisor brackets (+10° torque, 8° tip) should initially be positioned parallel to the floor to avoid premature distal root tip in the path of the erupting canines. If the canines are severely angulated, the slot positions may need to be significantly exaggerated to create mesial root tip and thus move the lateral incisor roots farther away. Alternatively, the right and left lateral incisor

brackets can be switched, reversing the prescription’s tip without affecting the torque.²

One drawback of adding mesial root tip to the lateral incisors is that their mesial incisal edges will extrude, creating an undesirable appearance with the lateral incisors longer than the central incisors (B). Therefore, to produce a proper smile arc, the lateral incisor brackets should be positioned slightly more incisally (C).

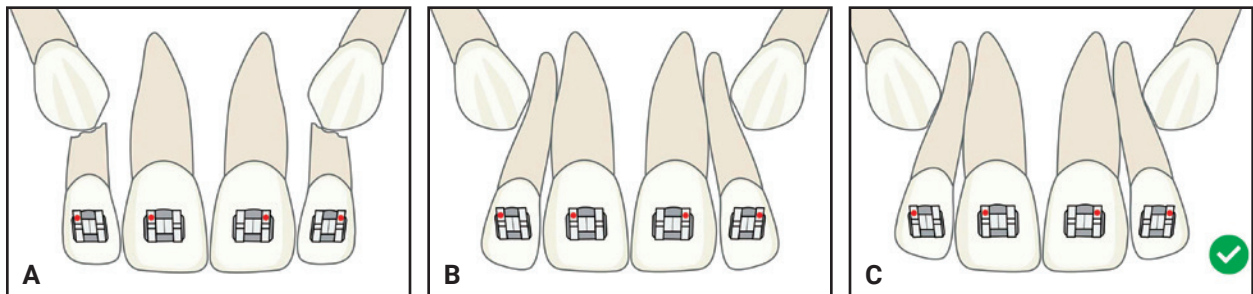
Discussion

Parents concerned about high-level esthetics during Phase I treatment should be informed of the rationale for mesial root tip of the lateral incisors. A brief midtreatment consultation to review the panoramic radiograph will usually suffice. If the parents insist, the lateral incisor brackets can be moved to their ideal positions later, after the canines have erupted further.

Overall, the goal of lateral incisor bracket positioning in Phase I is to create a funnel for safe eruption of the canines. If contact of the lateral incisor roots is suspected before treatment, however, the orthodontist should avoid bonding those teeth until the positions of the canines have improved, and then rectangular wires should be used judiciously. The risk of root resorption appears to

*Trademark of 3M, Monrovia, CA; www.3M.com.

**Registered trademark of Ormco Corporation, Orange, CA; www.ormco.com.



lessen as the canines slide farther down the roots of the lateral incisors.

The “ugly-duckling stage” of tooth development is often self-correcting, since the midline diastema will naturally diminish as the maxillary canines erupt and upright the roots of the incisors. This process is referred to as the Broadbent phenomenon. Broadbent cautioned against extensive orthodontic treatment focused on anterior alignment during this period. If fixed appliances are to be applied in Phase I, consider these tips to avoid any negative sequelae from orthodontic biomechanical forces.

REFERENCES

1. Broadbent, B.H.: Ontogenic development of occlusion, *Angle Orthod.* 11:223-241, 1941.
2. Kravitz, N.D. and Miller, S.: The rules of bracket flipping and switching, *J. Clin. Orthod.* 53:518-520, 2019.



NEAL D. KRAVITZ, DMD, MS
Associate Editor for Pearls
25055 Riding Plaza, Suite 110
South Riding, VA 20152
nealkravitz@gmail.com



SHAWN L. MILLER, DMD, MMedSc
Private practice, Orange, CA